

# Major Bleeding during Negative-Pressure Wound Therapy in Cardiac Surgery

Carmen Francis

Kent and Canterbury Hospital, UK\*

## ABSTRACT

Published on 30<sup>th</sup> March 2016

Infection of the sternotomy wound is potentially devastating and can sometimes cause lethal complications following cardiac surgery. Application of negative pressure by controlled suction through a porous dressing has emerged as a simple and effective treatment for a wide spectrum of surgical wounds. Negative-pressure wound therapy (NPWT) has been used for the treatment of deep sternal wound infection (DSWI) with promising results. However, questions have been raised regarding the potential risk of right ventricle or vessel rupture during treatment leading to major bleeding.

**Keywords:** Deep sternal wound infection, Negative pressure wound therapy, Right ventricular rupture

\*See End Note for complete author details

## INTRODUCTION

Negative-pressure wound therapy (NPWT), also known as vacuum-assisted closure (VAC), has been used successfully in DSWI treatment for a decade. With this method there are several advantageous features. VAC treatment allows open drainage that continuously absorbs the exudate with simultaneous stabilization of the mediastinal cavity and isolation of the wound. This method allows granulation tissue formation in combination with increased blood flow in the adjacent

tissue.<sup>1</sup> Concerns have been raised regarding the risk of right ventricle or vessel rupture and other bleeding complication that may be related to this technique. There may be several co-existing conditions, such as RV ischemia, RV dilation, severe tissue inflammation, and surgical trauma, which may cause spontaneous RV rupture.<sup>2</sup> The pathogenesis of major bleeding is not widely different from bleeding during open management of deep sternal wound infection, described by Robicsek in 1997<sup>3</sup> but is still widely unknown. To look more closely at the subject, we should look at

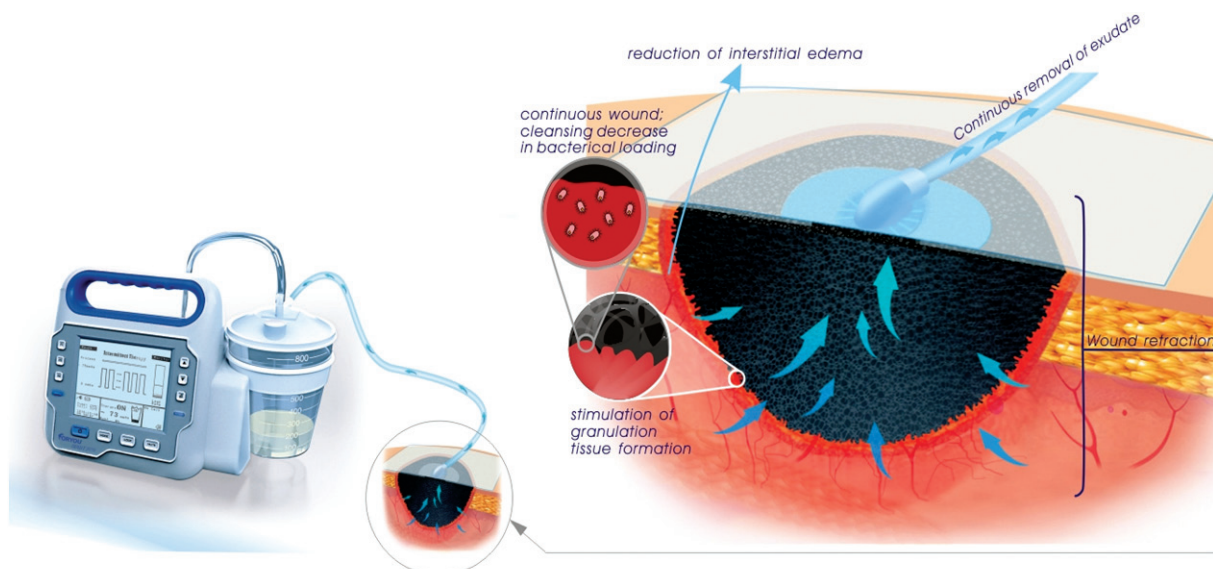


Figure 1. Mechanism of NPWT. (<http://www.foryounpwt.com/services/whatnpwt.html>)

Cite this article as: Francis C. Major Bleeding during Negative-Pressure Wound Therapy in Cardiac Surgery. IMA Kerala Medical Journal. 2016 Mar 30;9(1):36-39

### Corresponding Author:

Dr Carmen Francis, MUDr., Foundation Year 1 Doctor, Kent and Canterbury Hospital, UK.  
Email: carfrancis29@hotmail.com

other confounding factors such as microbiology, the interface dressing used, negative pressure settings, the frequency of dressing change and debridement, type of anticoagulation, site of coronary artery bypass graft if used, right heart failure and level of dependency i.e. if on ventilation.

## MICROBIOLOGY

Microbiology of sternal wound infections is variable. *Staphylococcus aureus* is the most common pathogen (29%), followed by *Staphylococcus epidermidis* (22%), with a notable frequency of *Pseudomonas aeruginosa*, methicillin-resistant staphylococci and streptococci, aerobic gram-negative rods, and anaerobes.<sup>4</sup>

To quantify bacterial load, biopsies are done. No significant difference was found between open wound management and NPWT. The total quantitative bacterial load was similar in both therapies. However, the incidence of *Staphylococcus aureus* infection was more significant in vacuum-assisted closure-treated wounds ( $p < 0.05$ ).<sup>5</sup> Another study by Baillot and colleagues showed that 4.9% infections were caused by methicillin resistant staphylococci and that *Staphylococcus epidermidis* was the most frequently reported pathogen. This was identified in up to 45% of the patients. In this study mortality was not influenced by sub species involved (6.68% vs. 9.28% for *S. epidermidis* and *S. aureus*, respectively).<sup>6</sup>

## INTERFACE DRESSING

Guidelines state that the foam dressing used in NPWT should be placed in direct apposition with the wound surface. However, an interface dressing is

often inserted at this point to promote comfortable dressing changes and to prevent from adherence and friction. Interface dressing affects pressure as the gauze dries out under topical negative-pressure and becomes strongly adherent to the wound surface. The loss of negative pressure means that pressure designated on the machine cannot be a reliable measure of pressure applied on the wound. This could be important in determining the outcome of negative-pressure wound therapy and major bleeding.

'Jelonet' is a Vaseline-impregnated gauze dressing that has been in use for many years. These can exert a mean pressure change of -11.76 mm Hg and a maximum of -41 mmHg due the pores in the foam being blocked by Jelonet.

## NEGATIVE PRESSURE SETTINGS

Interestingly, wound contraction seems to be observed at relatively low levels of pressure -40 to -80 mmHg and additional negative pressure does not increase wound contraction further. The advantage of greater wound contraction may lead to massive stimulation of granulation tissue and thus faster healing. However, this movement of the wound edges may cause damage to underlying organs causing rupture and bleeding. A report from Lund University, Sweden, indicates that there is less damage to the heart when using gauze than foam.<sup>8</sup> It is also recommends modifying technique by reducing the suction from -125 mm Hg to -70 mm Hg after 72 hours of treatment. In addition, routine placement of paraffin gauze over the surface of the RV before applying the suction dressing may help reduce adhesions and minimize trauma between dressing changes.<sup>9</sup>



Figure 2. Diagram showing the set up for NPWT and dressing. (<http://www.foryounpwt.com/services/whatnpwt.html>)

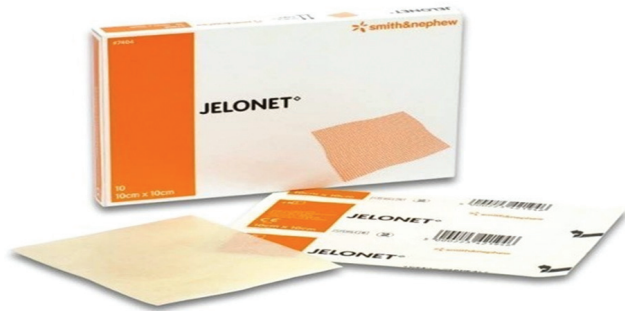

Figure 3. Jelonet dressing. (<http://homecaresupplies.ca/products/wound-care/dressings/jelonet-dressing.html>)

## FREQUENCY OF DRESSING CHANGES AND TOTAL PERIOD OF NPWT

There can be chronic wound-related problems in patients who have had VAC system for a prolonged duration. A report by Bapat<sup>10</sup> summarizes chronic complications of the sternal wound after prolonged use of VAC especially after its use to treat deep sternal infections. There were nine deaths, all due to unrelated causes, except in one patient who died of right ventricular rupture. Nine patients in one particular group had recurrent wound problems of which six had VAC system for more than 21 days. This is in contrast with 14 patients in another group who were treated with shorter duration of VAC who did not present with recurrent problems. During debridement and wound dressing changes, the right ventricle can be disrupted and bleeding can occur. It is recommended to change the foam thrice weekly. On the other hand, if dressings are not changed frequently, the wound is more susceptible to infection. Therefore, surgical expertise is crucial with debridement and use of interface dressing in order to protect the right ventricle.

## OVERVIEW

NPWT for DWSI has shown promising results. A study that looked at 30-day mortality in patients (n=176), who underwent cardiac surgery showed a mortality of only 1.1 % (over an 11 year period).<sup>11</sup> Furthermore, the study also showed that only 2.3% of patients suffered bleeding from RV rupture during NPWT.<sup>11</sup> This is in comparison to conventional treatment for DWSI, which has an associated bleeding risk of 5-21% and mortality of 15-50 %.<sup>12</sup> Though NPWT requires numerous surgical debridements, it is seen that conventional methods may also require such frequent interventions.<sup>13</sup>

The majority of patients that undergo cardiac surgeries such as Coronary Artery Bypass Graft, and

subsequently require NPWT, have co-morbidities that already pose a risk for major bleeding and other complications. Such risk factors include Chronic Obstructive Pulmonary Disease, Diabetes, Peripheral Vascular Disease, obesity and advanced age. Perioperative variables such as prolonged intubation and re-operations to manage bleeding further complicate major bleeding risks.

Though NPWT is associated with bleeding risk from RV rupture, the benefit of superior infection control seems to outweigh this potential complication.<sup>11</sup> The presence of the paraffin gauze as an interface between the polyurethane foam and anterior wall of the RV is vital in reducing this risk.<sup>11</sup> The paraffin gauze not only reduces the formation of adherence between the sternum and RV, but also reduces the negative pressure on the heart.<sup>11</sup> There is no indication for the applied topical suction to exceed -125 mmHg.<sup>11</sup>

Spontaneous RV rupture can occur due to sudden forward displacement of the RV, during coughing for example. This results in a shearing force between the sternal halves and both ventricles. This in turn requires meticulous removal of any sharp bony periosteal fragments and removal of all dehiscenced sternal wires at the very initial debridement. Lysis of adhesions between the anterior RV wall and sternal edges might be beneficial but paradoxically can precipitate haemorrhage. Infection related spontaneous RV rupture may be difficult to be distinguished from bleeding due to concurrent VAC therapy and may be a surrogate of overwhelming sepsis despite appropriate antimicrobial therapy.

## END NOTE

### Author Information

Dr. Carmen Francis, MUDr.,  
Foundation Year 1 Doctor, Kent and Canterbury  
Hospital, UK.

**Conflict of Interest:** None declared

## REFERENCES

1. Morykwas MJ, Argenta LC, Shelton-Brown EI, McGuirt W. Vacuum-assisted closure: a new method for wound control and treatment: animal studies and basic foundation. *Ann Plast Surg.* 1997 Jun;38(6):553-62.
2. Niclauss L, Delay D, Stumpe F. Right ventricular rupture due to recurrent mediastinal infection with a closed chest. *Interact Cardiovasc Thorac Surg.* 2010 Mar;10(3):470-2.
3. Robicsek F. Prevention of secondary hemorrhage in Hanuman syndrome (open mediastinal drainage). *J Cardiovasc Surg (Torino).* 1997 Dec;38(6):601-3.

4. Siegman-Igra Y, Shafir R, Weiss J, Herman O, Schwartz D, Konforti N. Serious infectious complications of midsternotomy: a review of bacteriology and antimicrobial therapy. *Scand J Infect Dis.* 1990;22(6):633-43.
5. Mouës CM, Vos MC, van den Bemd G-JCM, Stijnen T, Hovius SER. Bacterial load in relation to vacuum-assisted closure wound therapy: a prospective randomized trial. *Wound Repair Regen.* 2004 Feb;12(1):11-7.
6. Baillot R, Cloutier D, Montalin L, Côté L, Lellouche F, Houde C, et al. Impact of deep sternal wound infection management with vacuum-assisted closure therapy followed by sternal osteosynthesis: a 15-year review of 23 499 sternotomies. *Eur J Cardiothorac Surg.* 2010 Apr 1;37(4):880-7.
7. Jones SM, Banwell PE, Shakespeare PG. Interface dressings influence the delivery of topical negative-pressure therapy. *Plast Reconstr Surg.* 2005 Sep 15;116(4):1023-8.
8. Malmjö M, Lindstedt S, Ingemansson R. Effects of foam or gauze on sternum wound contraction, distension and heart and lung damage during negative-pressure wound therapy of porcine sternotomy wounds. *Interact Cardiovasc Thorac Surg.* 2011 Mar;12(3):349-54.
9. Abu-Omar Y, Naik MJ, Catarino PA, Ratnatunga C. Right ventricular rupture during use of high-pressure suction drainage in the management of poststernotomy mediastinitis. *The Annals of Thoracic Surgery.* 2003 Sep 1;76(3):974.
10. Bapat V, El-Muttardi N, Young C, Venn G, Roxburgh J. Experience with Vacuum-assisted closure of sternal wound infections following cardiac surgery and evaluation of chronic complications associated with its use. *J Card Surg.* 2008 Jun;23(3):227-33.
11. Johan Sjögren\*, Ronny Gustafsson, Johan Nilsson, Sandra Lindstedt, Shahab Nozohoor, Richard Ingemansson: Experience with Vacuum-Assisted Closure of Sternal Wound Infections Following Cardiac Surgery and Evaluation of Chronic Complications Associated with its Use