

A Pathological Surprise in the Urinary Bladder

Vivek Sharma^a, Vasudevan S^a, Krishna G^b

a. Department of Urology, Trivandrum Medical College; b. Department of Pathology, Trivandrum Medical College*

ABSTRACT

Published on 30th December 2016

Though urothelial tumours form a majority of Urinary Bladder neoplasms, occasional surprises do occur. Some of these do not have a characteristic presentation. They may be detected incidentally. Here we present a case of bladder paraganglioma which did not have the characteristic symptoms and signs of catecholamine excess. Hence the final pathological diagnosis was a pathological surprise.

Keywords: Paraganglioma Urinary Bladder, Asymptomatic, Soft Tissue Tumours Urinary Bladder

*See End Note for complete author details

INTRODUCTION

There are a variety of bladder tumours with their varied presentations. Most of them though tend to be urothelial carcinomas; there are many benign neoplastic lesions as well. Here we report one such rare case of bladder paraganglioma.

CASE REPORT

Gopalakrishnan, 65 year old male non smoker non alcoholic patient had presented to OPD with AUR one month back which had been managed by catheterization at a local hospital. There was history of haematuria preceding this acute urinary retention. He had no other urological complaint. Patient was a known diabetic and a history of coronary artery disease and there was a history of carcinoma tongue for which surgery done was done in 2007. Physical examination was unremarkable and so were his routine investigations. *No functional tests were done as no symptom or sign suggestive of catecholamine excess was seen at the presentation.* USG abdomen had shown a hypochoeic lesion of size 1.5 x 2.2 cm seen in the left lateral wall and further imaging with CECT revealed well defined soft tissue density polypoidal lesion measuring 19.8 x 18.4 x 17.3mm noted in the antero-inferior wall of urinary bladder towards midline with intraluminal extension without any calcification. Moderate enhancement on arterial phase with persistent enhancement on delayed images

was present but without any regional lymphadenopathy. Cystoscopy revealed a smooth bulge of 2 x 2 cm in size in the anterior wall and mucosa over it being normal, no biopsy was taken. Partial cystectomy was done on 20th August 2016 for this intramural lesion with 1.5 cm margin around. During the surgery, there were fluctuations in blood pressure with handling of the tumor. Specimen was sent for HPE (**Figure 1**). The post op period was uneventful and patient is on regular follow up.

Gross specimen: yellow circumscribed mass area 1.7 x 1.2 x 1cm size

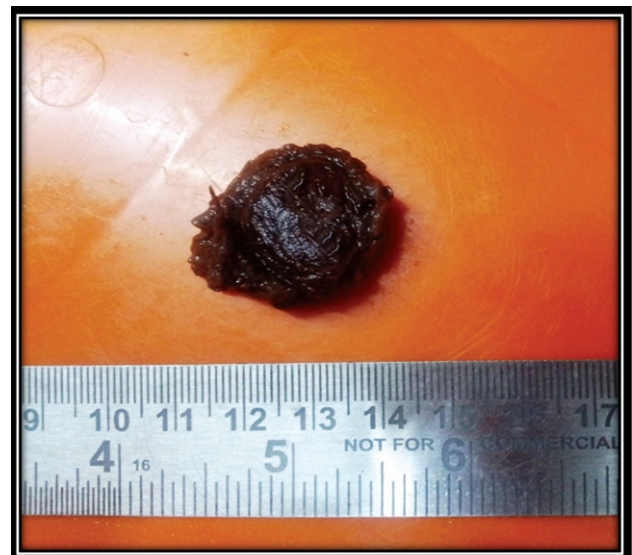


Figure 1. **Gross appearance**

Cite this article as: Sharma V, Vasudevan S, Krishna G. A Pathological Surprise in the Urinary Bladder. Kerala Medical Journal. 2016 Dec 30;9(4):174–6.

Corresponding Author:

Prof. Vasudevan S, Professor, Department of Urology, Trivandrum Medical College
E-mail: periamana@gmail.com

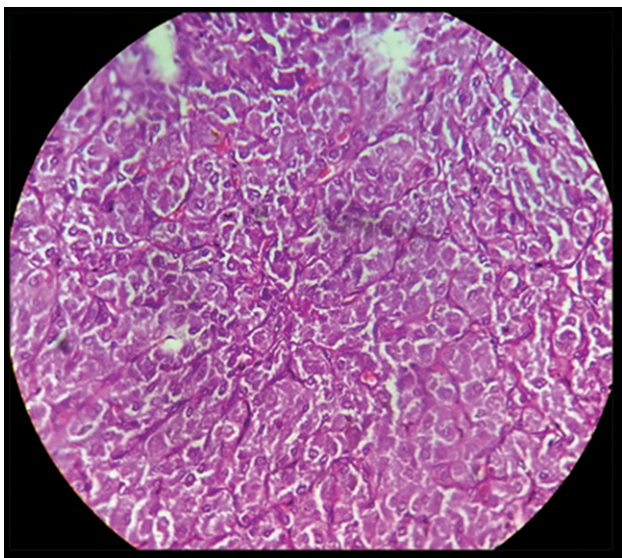


Figure 2. Stained appearance of the mass

HPE: Suggestive of paraganglioma

Resection margins are free of neoplasm

IHC: Chromogranin positive

Synaptophysin positive, NSE positive

S 100 positive, vimentin positive (Figure 2)

DISCUSSION

Paraganglioma is a neoplasm that originates from the paraganglion cells of the urinary bladder and is the same as paraganglioma at other site as in the head, neck, thorax, abdomen, and pelvis (including bladder). The chromaffin bodies that lie between the aortic bifurcation and the root of the inferior mesenteric artery are known as the organ of Zuckerkandl and are a common site for paraganglioma

In the genitourinary tract, the urinary bladder is the most common site for paragangliomas (80%), followed by the urethra (12%), pelvis and ureter. In urinary bladder most common site is the dome followed by the trigone, near ureteral orifice, dome and the lateral walls in the decreasing order.

EPIDEMIOLOGY

Paraganglioma of the urinary bladder is rare, accounting for less than 0.1% of all bladder tumors. It occurs in all age groups.^{1,2,3}

ETIOLOGY

The tumor arises from the ganglion cell in the bladder wall. Rarely, paraganglioma of the urinary bladder is associated with neurofibromatosis and urothelial

carcinoma. However, it is not related to any familial syndrome. Since paraganglia are distributed throughout the bladder wall, it can be found in any part of the bladder. They are mostly well circumscribed, and they form single small nodules, ranging from a few millimeters to a couple of centimeters. Multiple tumor nodules or tumoral aggregates are seen as well. Usually it is firm with a tan or dark brown cut surface. Placing the tumor in a Zenker's fixative turns the tumor to black in color; a positive chromaffin reaction helps in the gross diagnosis of the tumor. Microscopy can demonstrate what appears to be invasion of muscularis propria of the bladder wall, but on this basis alone the tumor SHOULD NOT be regarded as malignant. Immunohistochemistry (IHC) stain shows NSE, chromogranin and synaptophysin CD56, OCT4, S100 are positive in cells encircling the tumor cells (sustentacular cells).^{1,4,5,6} Vimentin is mostly positive in benign PGLs. Less than 7% UB paragangliomas are malignant. Absolute criterion for malignancy is the demonstration of metastasis.⁴ These express fewer neuropeptides than benign ones and have lower or absent S100 expression. Metastasis is mainly to regional lymph nodes, lungs and liver. High-grade urothelial carcinoma with a nest pattern, melanoma and carcinoid tumor come in its differential diagnosis. Immunohistochemical stains are useful in helping to establish these diagnoses.

Urothelial carcinoma and carcinoid tumor are positive for cytokeratin, while melanoma cells show positivity of S100, HMB45, and Melan A stains.

Presentation: As with other bladder tumors, hematuria is quite common. Persistent hypertension may be present and is quite specific. Since the paraganglioma secretes catecholamines, symptoms of headache, sweating, tremulousness, anxiety, and micturition syncope (the temporary loss of consciousness upon urinating).

In serum and urine markers of catecholamine excess can often help in the diagnosis.

Partial cystectomy is the treatment of choice.

END NOTE

Author Information

1. Dr. Vivek Sharma, Senior Resident, Department of Urology, Trivandrum Medical College
2. Prof. Vasudevan S, Professor, Department of Urology, Trivandrum Medical College
3. Prof. Krishna G, Professor, Department of Pathology, Trivandrum Medical College

Conflict of Interest: None declared

Editor's Remarks: Considering urinary bladder wall tumours Paragangliomas are rare tumours seen occasionally. When the characteristic symptoms and signs are present clinical suspicion is easy and diagnosis is often made promptly. Here the patient was asymptomatic and the pathological diagnosis came as a surprise. The case is reported for the unusual presentation of an uncommon case.

REFERENCES

1. Cheng L, Leibovich BC, Chevillat JC, Ramnani DM, Sebo TJ, Neumann RM, et al. Paraganglioma of the urinary bladder: can biologic potential be predicted? *Cancer*. 2000 Feb 15;88(4):844–52.
2. Heinrich E, Gattenloehner S, Mueller-Hermelink HK, Michel MS, Schoen G. Paraganglioma of urinary bladder. *Urol J*. 2008;5(1):57–9.
3. Linnoila RI, Keiser HR, Steinberg SM, Lack EE. Histopathology of benign versus malignant sympathoadrenal paragangliomas: clinicopathologic study of 120 cases including unusual histologic features. *Hum Pathol*. 1990 Nov;21(11):1168–80.
4. Safwat AS, Bissada NK. Pheochromocytoma of the urinary bladder. *Can J Urol*. 2007 Dec;14(6):3757–60.
5. Grignon DJ, Ro JY, Mackay B, Ordóñez NG, el-Naggar A, Molina TJ, et al. Paraganglioma of the urinary bladder: immunohistochemical, ultrastructural, and DNA flow cytometric studies. *Hum Pathol*. 1991 Nov;22(11):1162–9.
6. Kairi-Vassilatou E, Argeitis J, Nika H, Grapsa D, Smyrniotis V, Kondi-Pafiti A. Malignant paraganglioma of the urinary bladder in a 44-year-old female: clinicopathological and immunohistochemical study of a rare entity and literature review. *Eur J Gynaecol Oncol*. 2007;28(2):149–51.